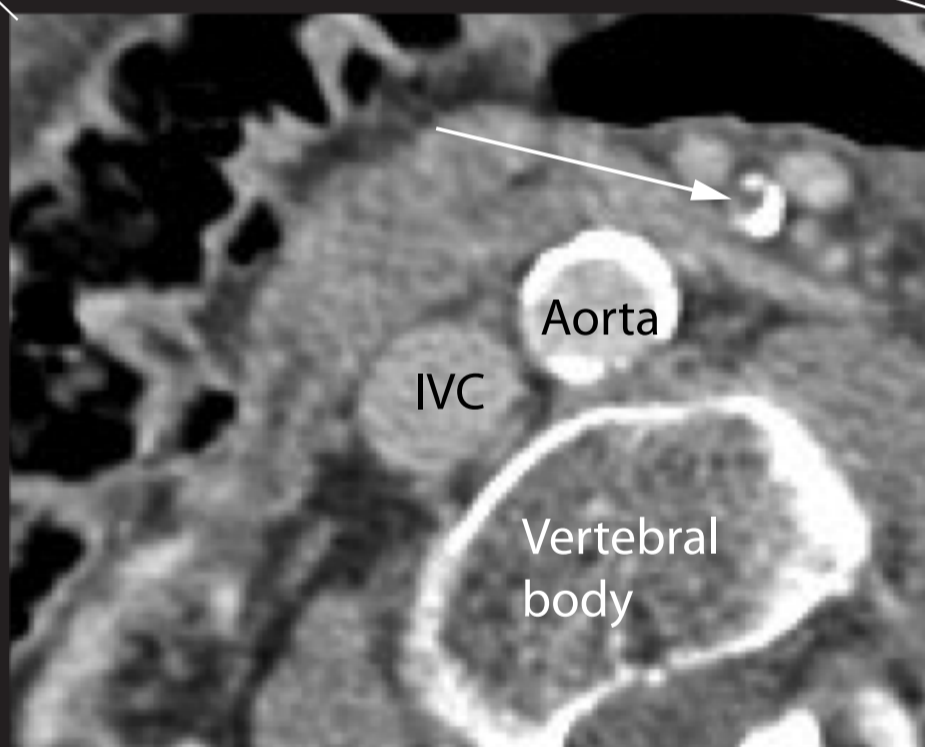
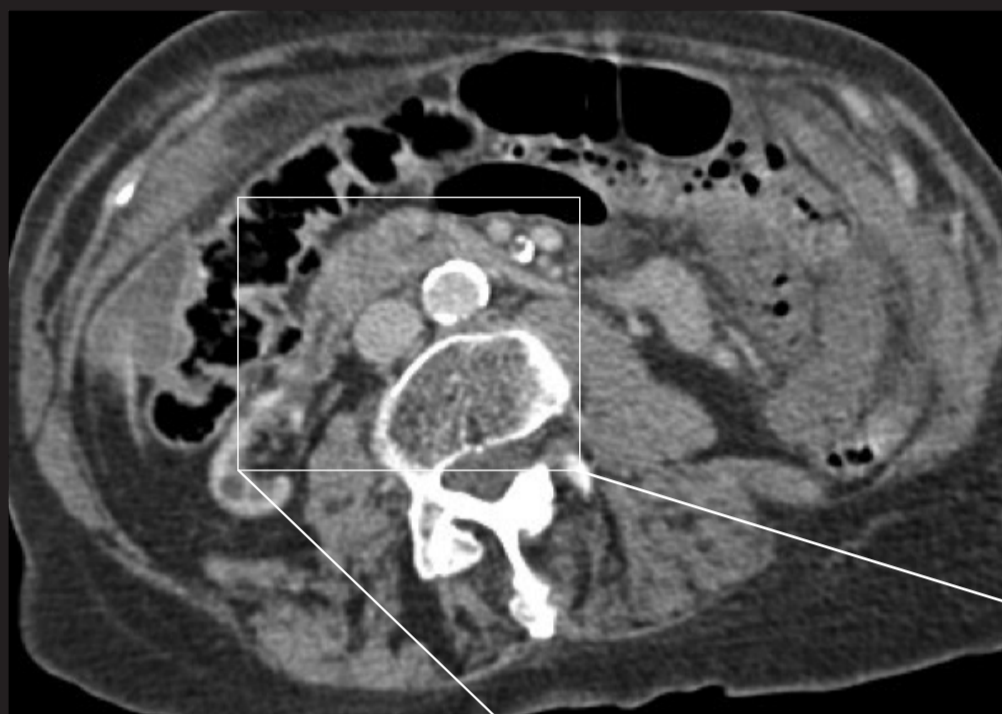
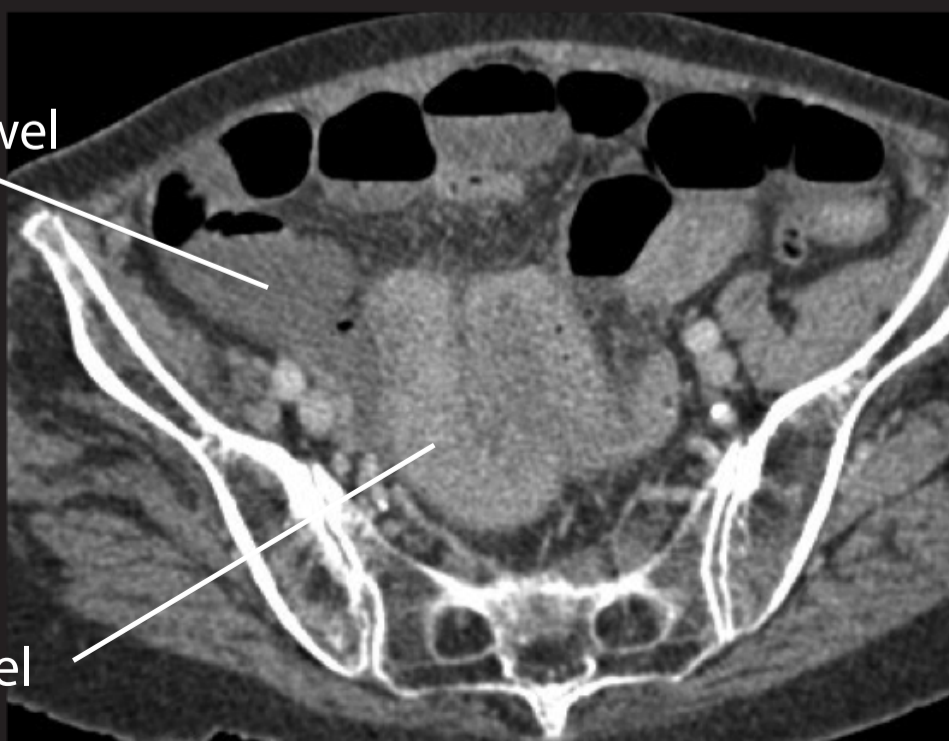

Mesenteric embolus.

Axial CT images in portal phase demonstrating an embolus in the distal superior mesenteric artery which is itself heavily calcified (as is the aorta) - see magnified image. The axial image (bottom) demonstrates enhancement of proximal ileum with contrast but no enhancement of distal ileum.



Non-enhanced
(ischaemic) bowel



Enhanced bowel